Existence of a Reactive Zone in the Interrenal Gland of Reptiles

As has been admitted in a relatively recent review on the reptilian adrenal gland[1], the data available in the literature in favour of the presence of differentiated zones in the interrenal tissue of these animals, are neither numerous nor conclusive. In fact, it is generally considered that, in this class of vertebrates, the interrenal gland presents a uniform disposition, both from the morphological and physiological points of view[2,3]. Scarce, isolated observations disagree with this current idea. Some of them concern structural[4,5] or histochemical[5,6] characteristics, while others bear upon histophysiological aspects[7,8,15].

These data, moreover, appear contradictory; thus, it seemed of interest to study this problem in the teiid lizard *Cnemidophorus l. lemniscatus* (L.), in which diverse experiments and observations regarding its endocrine system have been carried out.

Material and methods. Some adult males weighing between 9.2 and 15.5 g and with snout-vent lengths between 7.0 and 8.2 cm, received for 14 days a daily i.p. injection of 3 IU of corticotrophin (A. P. Acthar Gel Armour, 20 IU/ml); others were administered similar injections of 2.5 mg of metopirone bitartrate CIBA in aqueous solution[9]; and a 3rd group of animals, which served as controls, were injected distilled water only. A series of young males, with snout-vent lengths between 4.6 and 5.7 cm, was also studied; the smallest animals were in prepuberal state and the biggest ones had just completed their sexual maturation. In the testes of the former, there was no differentiated interstitial tissue and the spermatogenic process did not go beyond primary spermatocytes; in those of the latter, on the contrary, the cells of Leydig abounded and numerous spermatozoa were already formed. During the process of sexual maturation, together with the interstitiotrophs, the corticotrophic cells of the anterior hypophysis were activated[10]. 24 h after the last injection, the experimental animals, as well as the others immediatly after their capture, were anesthetized by ether and then decapitated. The adrenal glands were quickly removed and fixed in saline chromo-acetic formalin[11]. After paraffin embedding, transversal sections of 4µm were made and later stained with progressive iron haematoxylin-erythrosin-orange G-anilin blue[12], for study by the light microscope.

Results and discussion. In all the adrenals examined, a peripheral layer was observed, whose cells, by their arrangement, size and structure, could be easily distinguished from those situated in the centre of the gland (Figure 1). By its localization, this layer is contiguous to the peripheral chromaffin tissue and the epididymis. The cells are arranged in rounded, acinous-like formations, thus being differentiated from the central ones, which are generally disposed in anastomosing flat cords of 2 strata. The thickness of the peripheral layer is irregular, but for the most part consists of 1 or 2 acini. Almost always, its cells differ in size from those centrally situated; even when the cell boundaries may not be clearly distinguished, the fact is perceptible without difficulty by the distance separating the nuclei between them. The peripheral cells are smaller in the control adults and the prepuberal males (Figures 2 and 5), and larger in the adults treated with corticotrophin and metopirone (Figures 3 and 4); they have approximately the same size in males with a recent sexual maturation (Figure 6). In their structure, these cells also differ from the central ones, in a diverse way according to their size; when they have lesser dimensions, the nuclei are often smaller, irregular and with foldings in the membrane, and the cytoplasm contains less lipid inclusions; when they are larger, the differences are opposite: more vesiculous nuclei and cytoplasm richer in finely dispersed lipids. Even if the size does not differ to a great degree, there are structural characters which always allow the identification of either cellular type; in males just sexually matured, as in this case, the peripheral cells lack the

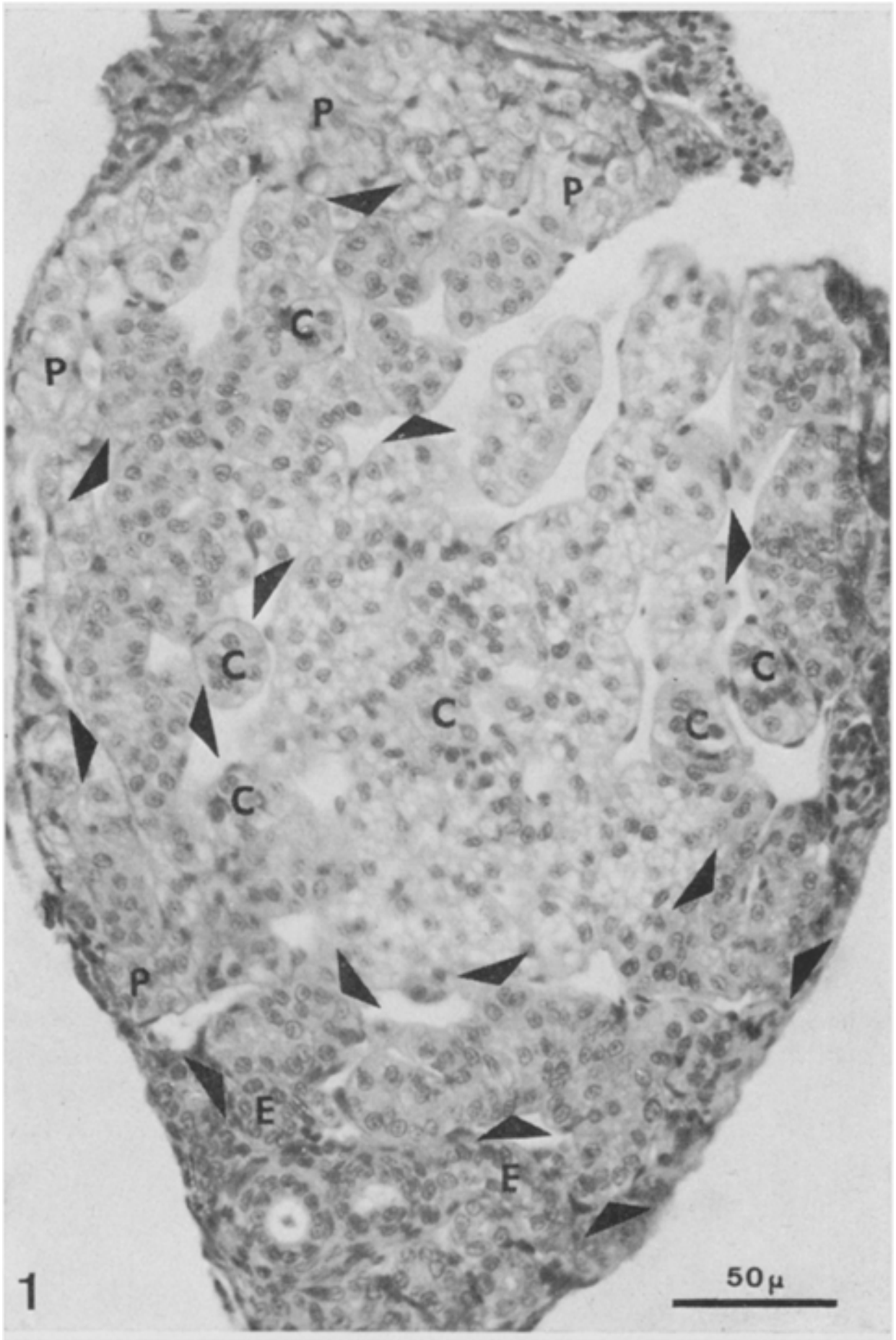

Fig. 1. Adrenal gland of a prepuberal lizard; transversal section. The reactive zone is indicated between arrows; by its external localization, it is adjacent to the peripheral chromaffin tissue, producer of norepinephrine (P), and the epididymis (E). The cells of the inner zone have larger lipid inclusions. C, central islets of chromaffin tissue, producer of epinephrine.

---

[1] M. Gabe, M. Martoja and H. Saint Girons, Année Biol. *3*, 303 (1964).

[2] F. A. Hartman and K. A. Brownell, *The Adrenal Gland* (Lea and Febiger, Philadelphia 1949).

[3] R. Bachmann, in *Handbuch der mikroskopischen Anatomie des Menschen* (Springer, Berlin 1954), vol. 6 (5), p. 63.

[4] E. W. Retzlaff, Anat. Rec. *105*, 19 (1949).

[5] M. Gabe and M. Martoja, Arch. Anat. microsc. *50*, 1 (1961).

[6] L. Arvy, C. r. Acad. Sci., Paris *255*, 1803 (1962).

[7] A. Wright and I. Chester Jones, J. Endocrin. *15*, 83 (1957).

[8] M. Martoja, R. Duguy and H. Saint Girons, Archs Anat. microsc. *50*, 233 (1961).

[9] E. Del Conte, Acta cient. venez. *22* (Suppl. 2), R-28 (1971).

[10] E. Del Conte, Acta cient. venez. *22* (Supl. 1), 28 (1971).

[11] E. Del Conte, Experientia *25*, 1330 (1969).

[12] M. Herlant, Archs Biol., Liège *67*, 89 (1956).

Figs. 2–6. Transversal sections of male lizard adrenals, with the same magnification. Between arrows, the reactive zone; P, peripheral chromaffin tissue; C, central islets of chromaffin tissue; E, epididymis.

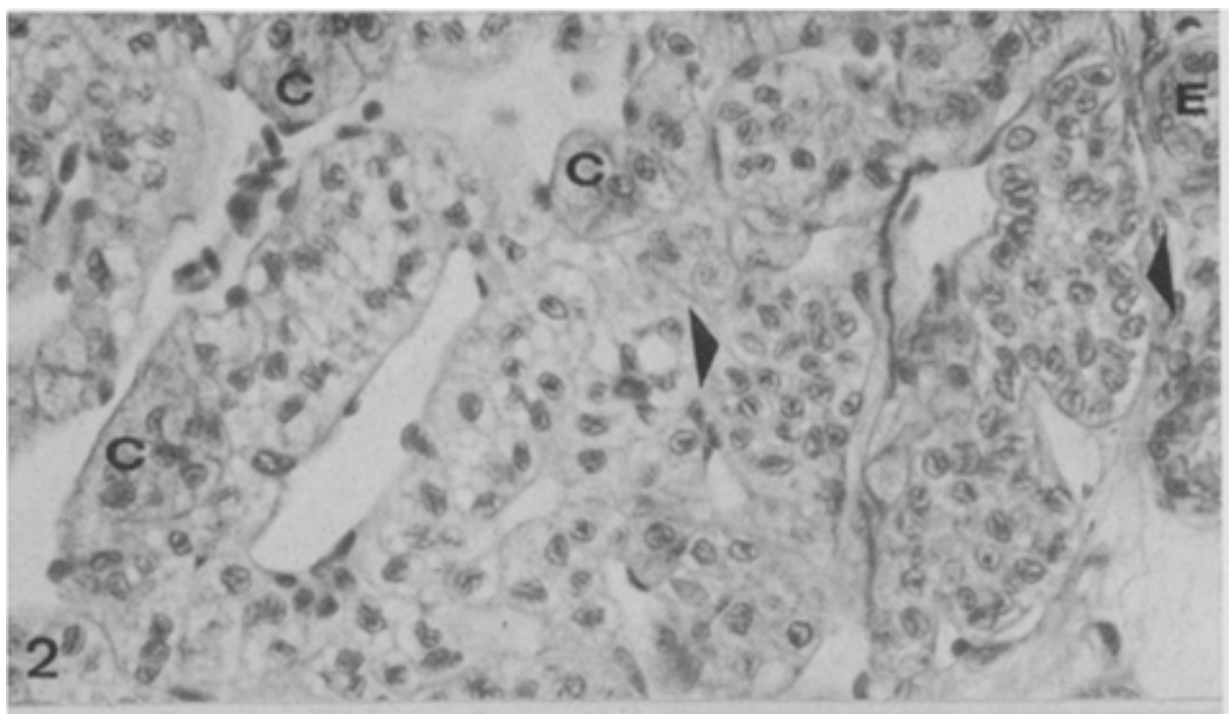

Fig. 2. Control adult lizard. The cells of the reactive zone are smaller and have less lipid inclusions than the central ones; the former are rather arranged in rounded formations, and the latter in anastomosed cords.

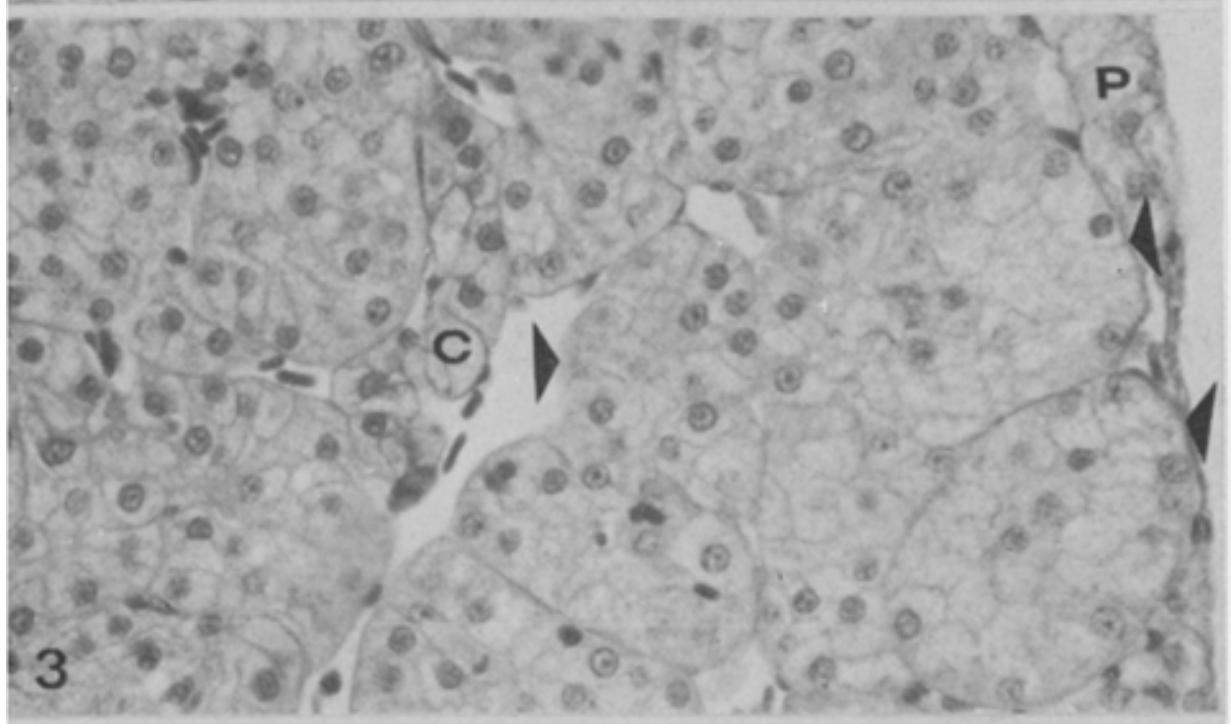

Fig. 3. After corticotrophin administration, the cells of the reactive zone become larger than those of the central zone, showing more vesiculous nuclei and a larger amount of finely dispersed lipids.

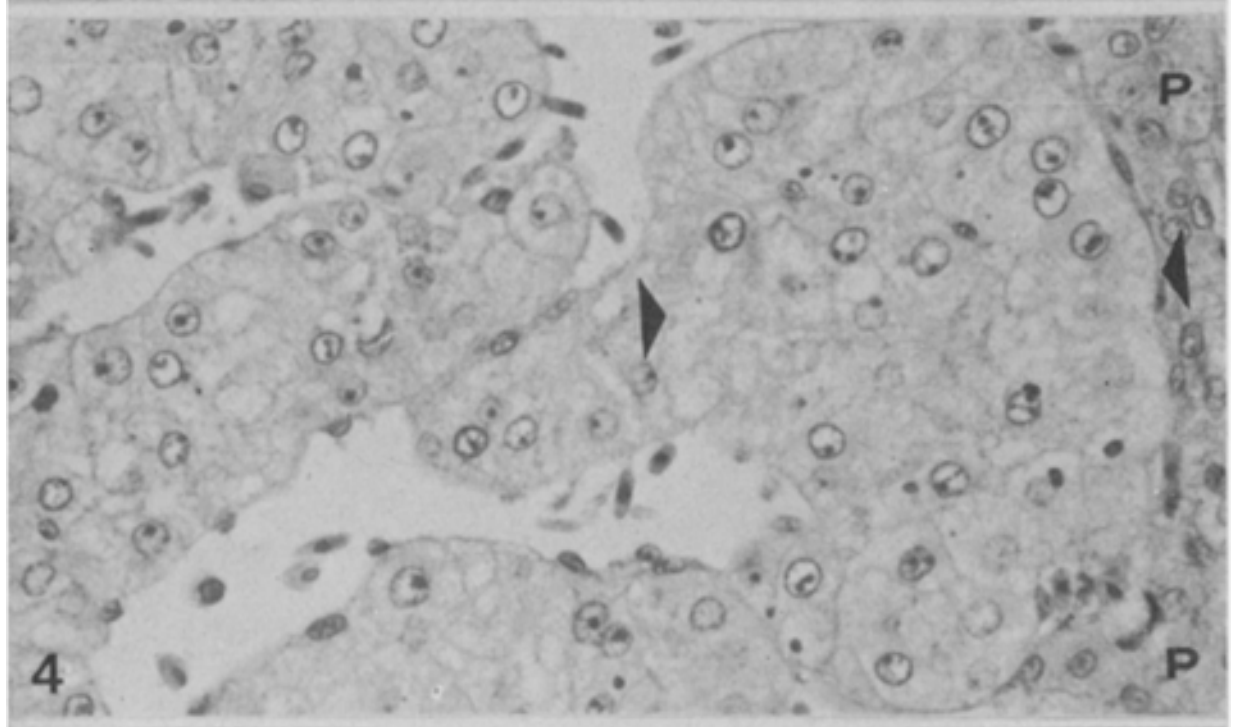

Fig. 4. In animals given metopirone, which causes an increased production of endogenous corticotrophin, the hypertrophy is also more pronounced in the reactive zone.

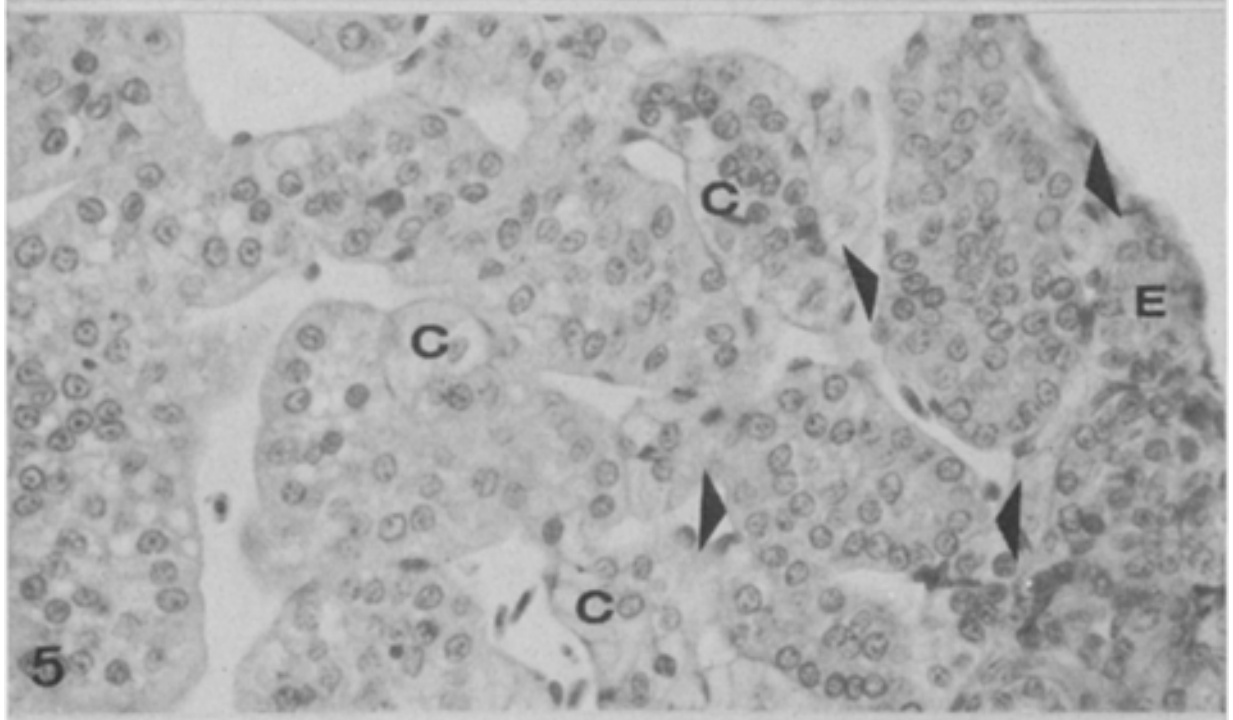

Fig. 5. In prepuberal lizards, the reactive zone is composed of small cells with scarce lipid inclusions.

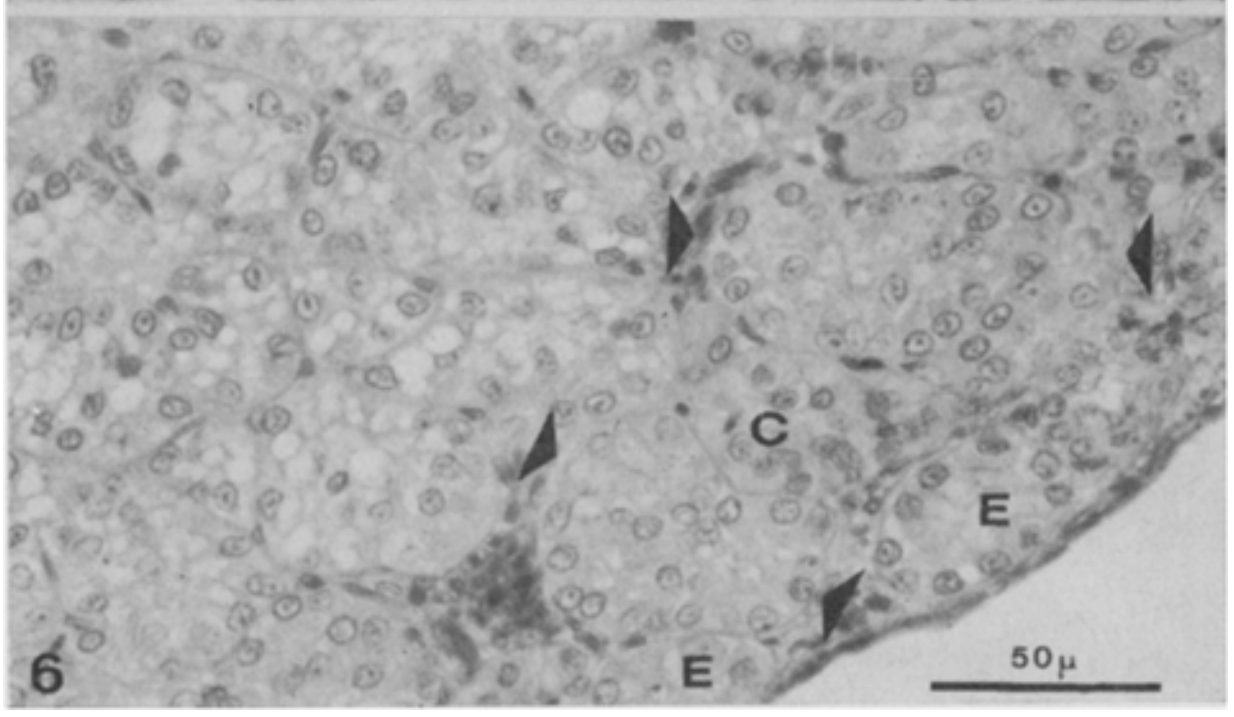

Fig. 6. When the spermatogenesis is just completed, and following a hypertrophy of the pituitary corticotrophic cells, an activation of the interrenal gland takes place, and is more notable in the reactive zone. The cells of the central zone are richer in large lipid inclusions.

large vacuoles corresponding to coarse lipid inclusions which, at least in this species – in *Agama agama* it seems to be different[7] –, are always more frequent in the central cells.

These findings make it possible to outline an interpretation on the whole, regarding the functional signification of the peripheral layer of interrenal cells in reptiles, as well as to understand the apparently contradictory data existing in the literature. Indeed, these cells are small and show histological signs of hypoactivity in control adults and prepuberal males, which coincides with that observed in normal specimens of other species[4–7]; but they react more rapidly and with a greater intensity than the central cells to the hypophyseal corticotrophic stimulus, quickly surpassing them in size and histological signs of hyperactivity. This is observed as well by effect of exogenous corticotrophin, as by the endogenous corticotrophin which is released consequently to metopirone administration[9], or which must be produced by the hypertrophic corticotrophs of sexually maturing animals[10]. Very probably, the springtime hypertrophy of the peripheral cells observed in some snakes[8,13] is, in a like manner, a response to a corticotrophic stimulus. On the other hand, these cells suffer the atrophy by lack of stimulus also in a more rapid and intense manner, as has been seen in hypophysectomized specimens of *Agama agama*[7]. It is evident that this layer reacts to the corticotrophin or to its absence with the same tendency as the remainder of the gland, but that it has a much greater sensitivity or responsiveness; for this reason it seems suitable to term it the reactive zone.

At present there is no evidence that the reactive and central zones of the reptile interrenal accomplish diverse functions with reference to the synthesis of hormones, as is generally acknowledged for the different zones of the mammalian adrenal cortex. In spite of its external situation and often smaller cells arranged in rounded formations, the reactive zone could be related, owing to its behaviour before similar stimuli, rather to the mammalian fasciculata than to the glomerulosa[2,14,15].

By its great sensitivity, the reactive zone of the interrenal gland of reptiles is evidently a useful index, which should be taken into account in the histophysiological studies concerning this organ.

Resumen. El estudio histofisiológico de la glándula interrenal de un lagarto teído (*Cnemidophorus l. lemniscatus*) permitió poner de manifiesto la que se denominó zona reactiva de la glándula. Por su situación es periférica, y está constituida por células dispuestas en formaciones redondeadas. Estas células, que tienen normalmente aspecto de menor actividad, responden más rápida e intensamente que las centrales a la acción de la corticotrofina, exógena o endógena, y aparecen entonces más activas que las últimas.

E. DEL CONTE

Facultad de Medicina, Universidad del Zulia,
Apartado 10.065, Maracaibo (Venezuela), 19 July 1971.

---

[13] B. LOFTS, J. G. PHILLIPS and W. H. TAM, Gen. comp. Endocr. *16* 121 (1971).

[14] H. SELYE and H. STONE, *On the Experimental Morphology of the Adrenal Cortex* (Thomas, Springfield 1950).

[15] C. BUGNON, D. LENYS and R. LENYS, Annls scient. Univ. Besançon, 2e sér., Méd. *6*, 145 (1962).

Intramitochondrial Complexes of Atypical Structures in Hepatocytes of *Triturus alpestris* (Laurenti)

Mitochondria showing atypical internal structure or the presence of various inclusions, both in physiological and pathological conditions, have been the subject of numerous publications[1–12]. During present studies on the fine structure of *Triturus alpestris* hepatocytes, complexes of atypical structures were observed inside some mitochondria.

Three adult males of *Triturus alpestris* reared in tap water were used in this study. Small pieces of the liver were excised and fixed for 1.5 h in 2% OsO_4 in phosphate buffer containing 2.5% sucrose. After dehydration the tissue was embedded in Epon 812[13]. Ultrathin sections were stained with Karnovsky's lead stain A[14] and examined in a Tesla BS 613 electron microscope.

Atypical structures in mitochondria were visible in sections in the form of complexes consisting of a few to a dozen or so elongated bodies localized non-specifically inside the mitochondrial matrix (Figures 1 and 2). Three types of organization of these complexes were ascertained. Complexes of the first type (Figures 2 and 4) contain the bodies of approximately 220 Å thick, arranged parallel, with distances of about 100 Å between them. The ends of these bodies form characteristic club-shaped dilatations. Each body has electron-opaque walls and a brighter core with centrally placed dense structure, approximately 38 Å wide. In the second type of complexes (Figure 3), the bodies show also characteristic dilatations at the ends, but they are devoid of the electron-opaque element and their walls show in sections a sinuous line. Their thickness, as well as the width of space between them, is similar to the previous case. The bodies of the third type (Figures 1 and 5) have, apart from electron-transparent club-shaped dilatations, certain features of crystalline structures. Some of their fragments show hexagonal organization under large magnification.

The electron micrographs obtained suggest that complexes of these atypical intramitochondrial structures represent, in respect to spatial configuration, systems of biconcave and closely assembled lamellae. This is supported by the fact that no sections through these bodies, under the form of circular profiles, corresponding to a tubular structure, were ever observed. Lamellar features of the complexes described suggest that most probably they re-

---

[1] C. ROUILLER, Int. Rev. Cytol. *9*, 227 (1960).

[2] K. BLINZINGER, H. B. REWCASTLE and H. HAGER, J. Cell Biol. *25*, 293 (1965).

[3] R. J. STEPHENS and R. F. BILS, J. Cell Biol. *24*, 500 (1965).

[4] E. G. GRAY, J. biophysic. biochem. Cytol. *8*, 282 (1960).

[5] HUAI-SAN LIN, J. Cell Biol. *25*, 435 (1965).

[6] E. J. WILLS, J. Cell Biol. *24*, 511 (1965).

[7] E. MUGNAINI, J. Ultrastruct. Res. *11*, 525 (1964).

[8] H. THEMANN und D. B. v. BASSEWITZ, Cytobiologie *1*, 135 (1969).

[9] T. SUZUKI and F. K. MOSTOFI, J. Cell Biol. *33*, 605 (1967).

[10] S. M. CHOU, Acta neuropath., Berlin *12*, 68 (1969).

[11] A. G. BHAGWAT, Arch. Path. *91*, 70 (1971).

[12] K. SHIRAKI and H. B. NEUSTEIN, Arch. Path. *91*, 32 (1971).

[13] J. H. LUFT, J. biophys. biochem. Cytol. *9*, 409 (1961).

[14] M. J. KARNOVSKY, J. biophys. biochem. Cytol. *11*, 729 (1961).